

VAISAKH KUZHIKKALI
DAVID VICTOR KUMAR IRUGU
HITESH VERMA
PRANKUR VERMA

Corresponding Author

Hitesh Verma

Assistant professor, Department of
otolaryngology , Head & Neck Surgery,
New Delhi

Email: drhitesh10@gmail.com

GRADE 2 SECONDARY RETROSTERNAL GOITER MANAGED WITHOUT STERNOTOMY- A CASE REPORT

ABSTRACT

Retrosternal goiter is used when more than 50% of thyroid mass lies below thoracic inlet. Retrosternal goiter is graded into 3 grades and it depend on inferior extension of thyroid mass. Grade 1 is defined when it lies above the aortic arch, grade 2 when it extends till pericardium, and grade 3 when it extends below right atrium. Grade 1 can be removed via cervical approach and grade 2 and 3 usually require sternotomy for complete removal. Here we discuss a case of Retrosternal goiter grade 2 removed via cervical approach without need of sternotomy.

Keywords: Goiter, Restrosternal, Sternotomy

INTRODUCTION

Retrosternal goiter is used when more than 50% of thyroid mass lies below thoracic inlet.^{1,2} Retrosternal goiter is graded into 3 grades and it depend on inferior extension of thyroid mass. Grade 1 is defined when it lies above the aortic arch, grade 2 when it extends till pericardium, and grade 3 when it extends below right atrium.³ De Souza and Smith⁴ proposed another grading system in which grade 1 defines any thyroid gland with part of it going below thoracic inlet, grade 2 as gland reaching level of aortic arch, grade3 as reaching level of T4, and grade 4 as greater than 50% of gland below thoracic inlet. Retrosternal goiter can be classified as primary and secondary type. Primary arises from the ectopic thyroid tissue in the mediastinum while secondary is direct extension of thyroid gland.⁵ The usual symptoms are respiratory distress, dysphagia, odynophagia, hoarseness, Horner's syndrome, superior venacaval obstruction syndrome. Computed Tomography (CT) is the imaging of choice to assess the grade and relationship with nearby structures.⁶ The incidence of malignancies varies from 3 to 21%.⁷ We are discussing here a case of grade 2 retrosternal goiter, which was managed by transcervical approach without sternotomy.

CASE REPORT

A 72 year old lady presented with complaints of progressive swelling in neck for fifteen years. She

had history of dyspnea in lying down position. Local examination revealed extension of mass from hyoid bone to sternum in vertical dimension and beyond the sternocleidomastoid muscle in horizontal dimension (left > right). Pemberton sign was found positive (figure I). On palpation, there was single, soft to firm swelling with bosselated surface and which extended below and behind sternum and lower limit was not appreciated even with swallowing. Both vocal cords were mobile. No other notable finding was seen.

Thyroid stimulation test was found very low and propranolol was prescribed. Contrast enhanced computed tomography scan (CECT) of neck and thorax showed enhancing single mass lesion arising from cervical thyroid with extension into right parapharyngeal space and both side hyoid bone superiorly. Great vessels in neck were displaced posterolaterally with compression of trachea and obliteration of trachea esophageal groove and it was reaching upto prevertebral fascia posteriorly. Inferiorly it reached below the level of arch of aorta with significant anterior compression of thoracic trachea and most of the vessels in superior mediastinum (figureII, III). Fine needle aspiration cytology revealed features of Bethesda category I.

The mass was excised via transcervical approach using large collar incision without sternotomy. Mass was separated from surrounding structures and vascularity was controlled by ligation of

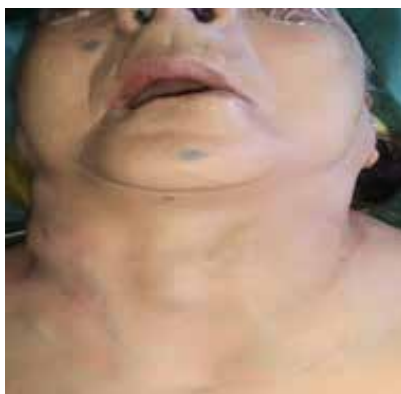

Fig I: Image of neck swelling

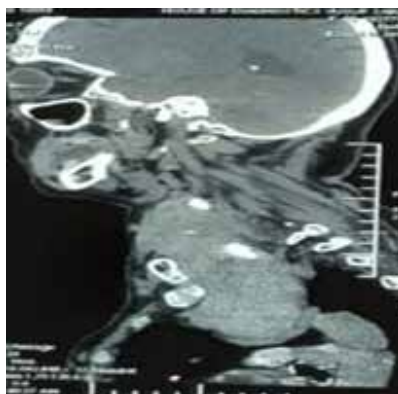


Fig II: CECT neck and thorax showing retrosternal extension of thyroid mass

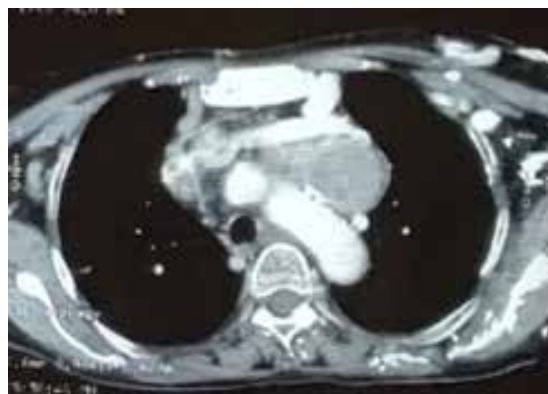

Fig III: CECT thorax showing retrosternal mass passing between the arch of aorta and brachiocephalic artery

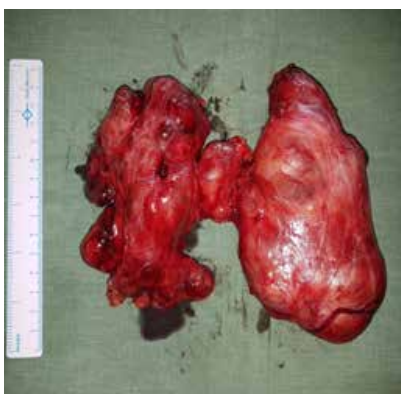

Fig IV: postoperative specimen after removal of thyroid mass.

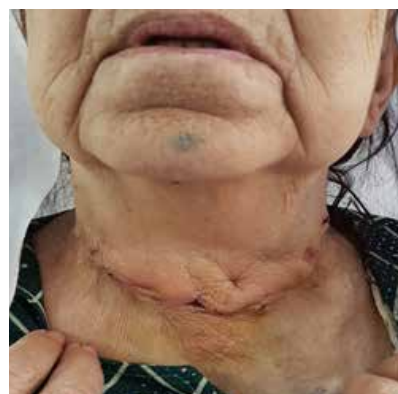

Fig V: clinical photo on first follow up visit

vessels. No feeder was found in Retrosternal (mediastinal) part of the swelling. Bilateral recurrent laryngeal nerves and right parathyroid glands were identified and preserved. Retrosternal part was separated from surrounding structure by blunt dissection and mass was removed in Toto. Final histopathology examination revealed features suggestive of multinodular goiter.

Left vocal cord paresis was noticed on 4th post operative day and it was recovered on first follow up visit. The patient is kept on thyroxine 100 microgram daily with regular monitoring of thyroid function test.

DISCUSSION

Grade 1 retrosternal goiters removal is possible by transcervical approach. Subsequent grades of retrosternal goiter require median sternotomy, posterolateral thoracotomy⁸ or a clam shell thoracotomy for complete exposure where as this case was managed by transcervical approach only.⁹ Transcervical excision without sternotomy is challenging as the retrosternal goitre can derive

its blood supply from vessels in thorax and can be hypervascular leading to excessive bleeding. We control all possible feeder before handling of mass by careful evaluation and ligation of all feeder. Prolonged tracheal compression can induced tracheomalacia which was not found intraoperatively so that successful extubation was done.¹⁰ Literature review showed sternotomy is indicated for retrosternal goitre with vertical extension at or below aortic arch, revision surgery, presence of mediastinal nodes and recurrent

and malignant tumours. The complications and morbidity associated with sternotomy approach is higher than the simple transcervical approach so decision should be made intraoperatively for higher grade secondary retro sternal goitres. Avoiding sternotomy also reduces the postoperative hospital stay and thus improves quality of life of patients as we saw in this case. Henceforth, this case highlights on the importance of attempting transcervical approach without sternotomy even in large retrosternal goiters extending below the aortic arch.

CONCLUSION

Grade 2 and 3 Secondary retrosternal goitre represents a great challenge for surgeons. Sternotomy is required for these masses. We here presented a grade 2 retrosternal goiter removed via transcervical approach which reduced morbidity associated with sternotomy as well as better quality of life and early recovery.

REFERENCES:

1. Agha A, Glockzin G, Ghali N, Iesalnieks I, Schlitt HJ. Surgical treatment of substernal goiter: an analysis of 59 patients. *Surgery today*. 2008;38(6):505-11.
2. Katlic MR, Grillo HC, Wang CA. Substernal goiter: analysis of 80 patients from Massachusetts General Hospital. *The American journal of surgery*. 1985;149(2):283-7.
3. Huins CT, Georgalas C, Mehrzad H, Tolley NS. A new classification system for retrosternal goitre based on a systematic review of its complications and management. *International Journal of Surgery*. 2008;6(1):71-6.
4. DeSouza FM, Smith PE. Retrosternal goiter. *The Journal of otolaryngology*. 198;12(6):393-6.
5. Rugiu MG, Piemonte M. Surgical approach to retrosternal goitre: do we still need sternotomy?. *Acta Otorhinolaryngologica Italica*. 2009;29(6):331-8.
6. Grainger J, Saravanappa N, D'souza A, Wilcock D, Wilson PS. The surgical approach to retrosternal goiters: the role of computerized tomography. *Otolaryngology—Head and Neck Surgery*. 2005;132(6):849-51.
7. Nervi M, Iacconi P, Spinelli C, Janni A, Miccoli P. Thyroid carcinoma in intrathoracic goiter. *Langenbecks Arch Surg*. 1998;383:337-9.
8. Chen X, Xu H, Ni Y, Sun K, Li W. Complete excision of a giant thyroid goiter in posterior mediastinum. *Journal of cardiothoracic surgery*. 2013;8(1):1-3.
9. Komninos G, Galata, G, Schulte KM. Giant recurrent intrathoracic goitre treated by clamshell thoracotomy and reverse sternotomy. *BMJ Case Rep* 2014;2014.
10. Al Hashemy A, Gallo R, Shah MT, Al Faifi A, Al Amir A, Al Shraim M, et al. Giant intrathoracic goitre: The challenges. *International Journal of Surgery Open*. 2016;2:6-10.

