

Rayamajhi P  
Karna S L  
Khanal K

Ganesh Man Singh Memorial Academy of ENT and Head & Neck Studies, TU Teaching Hospital, Maharajgunj, Kathmandu, Nepal.

#### Correspondence to:

Dr. Pabina Rayamajhi  
Department of ENT and Head & Neck Surgery,  
Ganesh Man Singh Bhawan  
TU Teaching Hospital, Maharajgunj,  
Kathmandu, Nepal.  
Email: pavina\_r@yahoo.com.

## OUTCOME OF COCHLEAR IMPLANT SURGERY IN TUTH

#### Objective:

To evaluate the preoperative hearing and the radiological status of the patients undergoing cochlear implant surgery. To evaluate the postoperative speech rehabilitation of patients undergoing cochlear implant surgery in TU Teaching hospital.

#### Materials and Methods:

A prospective, longitudinal study of 45 patients undergoing cochlear implant surgery from December 2004 to December 2012 was carried out in the department of ENT and Head & Neck Surgery, Ganesh Man Singh Memorial Academy of ENT and Head & Neck Studies, TU Teaching Hospital, Kathmandu, Nepal

#### Results:

Out of 45 patients, 26 were female and 19 were male. All patients had profound sensorineural hearing loss preoperatively. The preoperative imaging showed labyrinthine ossification in 2 patients. 93.3% (42) patients had good speech recovery postoperatively.

#### Conclusion:

Cochlear implant surgery is done for hearing rehabilitation in patients with bilateral profound sensorineural hearing loss. The surgery gives better result in postlingual patients, shorter duration of hearing loss and in children with highly motivated parents.

**Key words:** Cochlear implant, Prelingual, Postlingual deafness

#### INTRODUCTION:

Cochlear Implant surgery is a means of auditory rehabilitation in both adults and children. They are not simple hearing aids devices and thus require thorough preoperative evaluation of the patients and complex surgical procedure. It is done in patients with severe to profound sensorineural hearing loss who receive minimal or no benefit from the conventional hearing aid. Increasing number of surgeries are being done as there is a great burden of hearing loss in children globally. If done early, these patients are benefitted a lot. The implant surgery is done in great numbers in the west from many years. Many countries in Asia and even our neighbouring countries have been doing much in this field of implant surgery. The implant surgery and the devices are showing rapid development in the coming years. In the initial days of 1970s single channel device was used. Now there has been a rapid progression from the use of single channel devices to multi channel ones. The use of multi channel device greatly improved the speech understanding and spoken language performance specially in children<sup>1,2</sup>. The cochlear implant surgery was initially done in adults with FDA approval in 1984 and later in 1990 only, FDA approval for implant in children was given. In regards to prelingually deafened children nowadays it is advisable to do implant surgery as early as possible for better results. Various surgeons have quoted better results in surgeries done as early as possible. Hearing loss has to be intervened early as it will interfere with the development of speech, language, cognitive and socioeconomic behaviour<sup>3</sup>. Rapid development of speech perceptive skills and good listening skills was achieved in children implanted early<sup>4,5,6</sup>. Nowadays there is a trend of doing bilateral cochlear implant surgery too in many countries. Surgeons have shown it to be beneficial of spatial localization and better speech perception<sup>7</sup>. The disadvantage of such bilateral implants in our part of the world is the high cost to be managed by patients. The cochlear implant surgery is a complex surgery and needs multidisciplinary approach. The Otologists, Speech Pathologists, Psychologists, Paediatrician, Radiologists all are needed for their expertise. Greater role is played by the parents too as they need to be highly motivated. The outcome of surgery is not achieved in the immediate postoperative period but over a long period of time. The aim of doing this study is to evaluate the patients undergoing cochlear implant surgery in our institution for the last 9 years. This is a pioneer study in our country as the cochlear implant surgery is done only in our institute in the whole of Nepal.

#### MATERIALS AND METHODS:

This prospective study was conducted in the department of ENT and Head & Neck Studies, Ganesh Man Singh Memorial Academy (GMSMA) of ENT and Head & Neck Studies, TU Teaching Hospital, Kathmandu, Nepal from December 2004 to December 2012. This surgery needs a multidisciplinary role. Thus, department of Audiology & Speech, Paediatrics, Radiology and Psychiatry was consulted for every patient. Total number of 45 surgeries was done during this period.

Patients with severe to profound bilateral sensorineural hearing loss with no benefit from the conventional hearing amplification were included in the study. Patients with active middle ear disease, mental retardation, psychosis, organic brain dysfunction, severe labyrinthine obliterans, cochlear agenesis, very small internal auditory canal (cranial nerve VIII atresia) were excluded from the study. Taking into consideration of the above criterias, patients were selected in the Otolaryngology outpatient department (OPD). Detailed history and the examination of the patients were done. All patients had a trial of conventional hearing aid device had no benefit by it. Specifically, history of meningitis, other associated syndromes, birth history were taken for children undergoing implant surgery. Psychological evaluation was done in all the children with evaluation of their IQ status. Only patients with normal psychological status are included. Similarly, Paediatric consultation was done in all the children planned for surgery. Battery of audiological test was done in all patients. The audiological tests done were Behavioural observation audiometry, Tympanometry, OAE, ABR and Aided threshold tests. High resolution CT scan and MRI of the temporal bone was done and evaluated by senior radiology professor. Once all the investigations were done and patient were scheduled for surgery, they were vaccinated 2 weeks prior to surgery. Vaccination against Pneumococcus, Haemophilus influenza, Meningococcus and Hepatitis B were given. Patients scheduled for operation were admitted 2 days prior to surgery. Broad spectrum antibiotics like coamoxyclav, tobramycin, ceftriaxone were given preoperatively, preoperatively and continued for 10 days postoperatively. Cochlear and Medel implant devices were used. The surgery was done under strict aseptic technique by two senior surgeon in the department. After the implant was kept and the wound sutured mapping was done by the senior audiologist. The patient was kept in the hospital for the next 10 days with alternate day dressing. Plain X-ray was done in the 1<sup>st</sup> postoperative day for the evaluation of the placement of the device. Once the suture was removed the

patient was discharged. Routine follow up was done by the surgeon. Switch on of the device was done in 4-6 weeks and then speech therapy was started by the senior audiologist and speech pathologists.

## RESULTS:

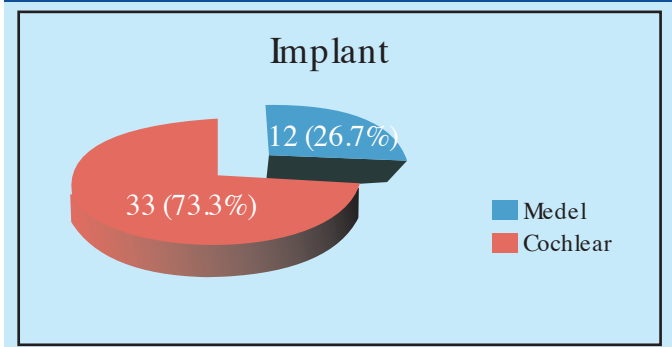
Total of 45 patients had undergone cochlear implant surgery from December 2004 to December 2012. Only 3 patients out of them (6.6%) had postlingual deafness and the rest 42 patients had no speech development preoperatively. 14 patients (31.1%) out of them followed lip reading. The preoperative audiometric response showed all the patients had bilateral severe to profound sensorineural hearing loss. All the patients taken for surgery had good IQ by psychological evaluation done preoperative. None of the child had syndromic deafness. Out of the total, 43 patients had insignificant past medical history except one who had past history of meningitis, thirteen months prior to surgery. That particular patient showed mild labyrinthine ossificans in the preoperative CT scan of the temporal bone. Rest of the patient had normal labyrinth in the preoperative imaging scans. Preoperative ventilation tube insertion was done in 3 patients (6.6%) around 2 weeks prior to implant surgery. There were total of 26 female patients (57.8%) and 19 male patients (42.2%). The age distribution of the patient is as shown in the Table 1. The maximum number of patients are in the age group of 3 and 4 years.

Tab.1: Showing the Age distribution of the patients. (n=45)

Age (years)	Number of patients	Percentage (%)
<2 yrs	8	17.8
3-4yrs	19	42.2
5-6yrs	6	13.3
7-8yrs	6	13.3
9-10yrs	4	8.9
>10yrs	2	4.5

The implants used in the patients were either Medel or Cochlear. The distribution was as shown in the figure 1 below.

Fig.1: Showing the type of the implants (n=45)



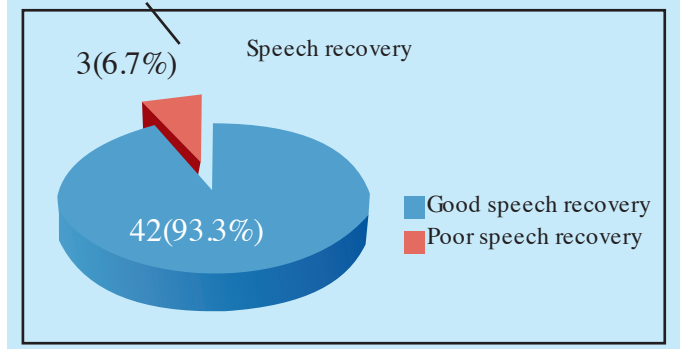
Various speech processors like Spirit, Freedom and CP 810 were used. Among the total patients; 42 patients (93.3%) had surgery in the right ear. Regarding the implant electrode insertion 39 patients (86.7%) had complete insertion. 2 patients (4.4%) had poor insertion with only 4 active electrodes in full insertion. Those patients had poor postoperative Neural Response Telemetry (NRT). There was no major complication noted during the surgery or in the postoperative period. Complications noted were mentioned as in Table 2. In the patient who had no development of NRT post insertion of the electrode had to undergo revision surgery. He was a child with labyrinthine ossificans and even after revision surgery complete insertion was till the 4th active electrode. Among the patients with facial palsy all had transient facial palsy and had complete recovery. Hematoma in one patient developed in 3rd day of surgery, drained and fully recovered on discharge. Another patient had developed hematoma in 6 weeks and was readmitted. The wound was drained and intravenous antibiotics was given after which he had good recovery and was discharged. Wound infection in one child was noted after 2 years of surgery and was treated by oral antibiotics in OPD basis. Speech therapy was started in all patients after switch on was done around 6 weeks of

Tab.2: Peri and postoperative complication. (n=45)

Complication	Number of patients	Percentage
No development of NRT	1	2.2%
Facial nerve palsy	3	6.7%
Hematoma	2	4.4%
Wound infection	1	2.2%

surgery. 42 patients (93.3%) patients showed good speech recovery postoperatively. There was no improvement or very poor improvement in 3 patients as shown in figure 2.

Fig. 2: Speech rehabilitation after cochlear implant. (n=45)



Among the three patients who had poor speech improvement one was a child with labyrinthine obliterations and poor NRT development, another was 15 yrs old girl with prelingual deafness and third was 52 years old male patient who had incomplete insertion of the active electrode. Good speech recovery was noted more in children who had highly motivated parents especially mothers who had active participation in providing good stimulus to their children.

## DISCUSSION:

Cochlear implant surgery is an advanced surgery done for rehabilitation of the patients with bilateral sensorineural hearing loss. We are still in the preliminary stage of doing implant surgery as compared to many developed countries. Our study included patients who were either postlingual adults or higher number of prelingual children. All of our patients had bilateral sensorineural hearing loss not helped by the conventional hearing aids. None of our patients had syndromic deafness. All of them had good IQ in preoperative psychological evaluation. So, we have limited experience in dealing with patients with syndromic deafness. Broomfield et al showed variable results of improvement in syndromes like Usher, Waardenburg, Pendred etc in their series of 38 syndromic patients. After a follow up of 19 months 55% of the children achieved a Speech reception score of level six. He observed significant variation of outcome between and within syndrome groups<sup>8</sup>. Qadeer et al reported successful cochlear implant surgery in a patient with Mondini's deformity in Aga Khan university hospital in Pakistan<sup>9</sup>. In our series of cochlear implant we had one patient with the history of meningitis and his preoperative CT scan showed mild labyrinthine ossificans. His first surgery was not successful and thus had to be reimplanted. Durisin et al reported his experience of performing cochlear implant surgery in his series of 30 children and 11 adults with labyrinthine ossificans<sup>10</sup>. He observed that labyrinthine ossificans were detected more frequently in imaging when there is a greater interval between the onset of meningitis and the CT scan performed. From his experience he concluded that cochlear implantation should be performed bilaterally as early as possible after meningitis<sup>10</sup>. Maximum number of patients in our series were in the age group of 3-4 years (42.2%). There were all with prelingual deafness. Majority of the patient in this age group showed good postoperative speech rehabilitation. The youngest patient was 1 year old. In 2000, the Food and Drug Administration lowered the age of eligibility to 12 months. Martini et al<sup>11</sup> showed better hearing and linguistic results in children implanted at earlier age. He also stated a sensitive period under 24-36 months over which implantation is reported to be less effective. Postoperative complication in our study were seen in 7 patients (15.5%) among the total patients of 45.

Minor complications like transient facial palsy (6.7%), wound infection (4.4%) and hematoma (2.2%) was reported and they were all managed without sequelae. One of them had the major complication of NRT not developing in the postoperative period and thus had to be reimplanted. Darlong et al<sup>12</sup> reported various surgical complication in his large series of 190 patients like CSF leak without meningitis (3.25%), device migration/failure (1.05%) and flap infection (1.57%). Similarly, Ikeya et al<sup>13</sup> reported 8.7% complication rate in their series of 406 cochlear implant surgery in Tokyo Medical University. 30 of their cases required revision surgery mainly for flap necrosis. Mc Jenkin et al<sup>14</sup> reported in their series of 165 patients flap infections in 2.6% and hematomas in 1.9% which was comparable to our study though sample size is very less in our study.

We need to make a larger series of patients to really assess our outcomes and the complications of cochlear implant surgery in our centre. The main drawback in having less surgery is the lack of awareness about the surgery and its benefit among the parents. We also have the financial constraints as this surgery is costly and we lack insurance policy in surgery. There is still a long way to go for us into the future of bilateral implants<sup>7</sup> and hybrid implants but still lots of patients in our country is being benefitted by the surgery. Our goal is to focus on bringing these children into early rehabilitation after the surgery and bring them into the mainstream.

#### CONCLUSION:

Cochlear implant surgery is done for rehabilitation of bilateral severe to profound sensorineural hearing loss. The surgery needs a multidisciplinary approach. Better result is obtained if the surgery is done early and needs good motivation from the parents too. Though there is a financial constraint we need to make more parents aware of the need of surgery in the early age for good speech rehabilitation.

#### REFERENCES:

1. Clark G. The multichannel cochlear implant and the relief of severe to profound deafness. *Cochlear implants Int.* 2012; May 13 (2): 69-85.
2. Clark G. The multi-channel cochlear implant: past, present and future perception. *Cochlear Implants Int.* 2009; 10supl 1: 2-13.
3. Deltenre P, Van Maldergem L. Hearing loss and deafness in the pediatric population: causes, diagnosis and rehabilitation. *Handb Clin Neurol* 2013; 113: 1527-38.
4. Low WK, Bin Iskandar MF, Sarepaka GK. Outcome of early cochlear implantation. *Ann Acad Med Singapore* 2008 Dec; 37: 49-3.
5. Tomblin JB, Barker BA, Spencer LJ, Zhang X, Gantz BJ. The effect of age at cochlear implant initial stimulation on expressive language growth in infants and toddlers. *J Speech Lang Hear Res* 2005 Aug; 48 (4): 853-67.
6. De Raeve L. A longitudinal study on auditory perception and speech intelligibility in deaf children implanted younger than 18 months in comparison to those implanted at later ages. *Otol Neurotol* 2010 Oct; 31 (8): 126-7.
7. Dorman MF, Spahr AJ, Loiselle L, Zhang T, Cook S, Brown C, Yost W. Localization and speech understanding by a patient with bilateral cochlear implants and bilateral hearing preservation. *Ear Hear.* 2013 Mar-April; 34 (2): 245-8.
8. Broomfield SJ, Bruce IA, Henderson L, Ramsden RT, Green KM. Cochlear implantation in children with syndromic deafness. *Int J. Pediatr Otolaryngol* 2013 aug; 77 (8): 1312-6.
9. Qadeer S, Junaid M, Sobam ZA, Nadeem N, Awans MS. Cochlear implant in a patient with Mondini's deformity of the cochlea: pilot study in Pakistan. *J Pak Med Assoc* 2013 Jul; 63(7): 913-5.
10. Durisin M, Bartling S, Arnoldner E, Ende M, Prokein J, Lesinski-Schiedat A et al. Cochlear osteogenesis after meningitis in cochlear implant patients: a retrospective analysis. *Otol Neurotol* 2010 Sep; 31(7): 1072-8.
11. Martini A, Bovo R, Trevisi P, Forli F, Berrittini S. Cochlear implant in children: rational, indications and cost efficacy. *Minerva Pediatr* 2013 Ju; 65 (3): 325-39.
12. Darlong V, Khanna P, Baidya DK, Chandra Lalchen, Pandey R, Punj J, Kumar R, Sikka K. Perioperative complications of cochlear implant surgery in children. *J Aneshth* 2014. Jul 2 ( epub ahead of print)
13. Ikeya J, Kawano A, Nishiyama N, Kawaguchi S, Hagiwara A, Suzuki M. Long term complication after cochlear implantation. *Auris Nasus Larynx* 2013 Dec; 40(6):529-9.
14. Mc Jenkin J, Jeya Kumar a. Complication in Pediatric cochlear implants. *Am J Otol laryngol* 2010 Mar-Apr; 31(2): 110-3.