

Gill J S  
Bhardwaj B  
Anand V  
Singla S

Shri Guru Ram Dass Institute of Medical  
Sciences and Research  
Amritsar, Punjab, India

**Corresponding to:**  
Dr. Bhanu Bhardwaj  
27-C Sant Avenue  
The Mall, Amritsar(143001), Punjab, India  
Email: entwithdrbhanu@gmail.com

## THE COMPARATIVE ROLES OF X-RAY NASOPHARYNX AND NASAL ENDOSCOPY IN DIAGNOSIS OF ADENOID HYPERTROPHY

### Objective:

The objective of this study was to compare the diagnostic efficacy of traditional X-ray Nasopharynx with upcoming Nasal endoscopy in grading of adenoid hypertrophy.

### Materials & Methods:

It is a prospective study of 40 school going children with symptoms and signs suggestive of adenoid hypertrophy. The preoperative grading of adenoid hypertrophy was done on Xray nasopharynx lateral view which was compared with a preoperative adenoid grading done with the rigid nasal endoscopy.

### Results:

A proper grading technique of adenoid hypertrophy as cited by Fujioka et al on Xray nasopharynx makes it an excellent diagnostic tool which is in comparison to direct visualisation and grading with nasal endoscopy. The comparison is statistically significant with  $p < 0.005$ .

### Conclusion :

The roles of X-ray nasopharynx and preoperative nasal endoscopy are both complementary and supplementary in the diagnosis and grading of adenoid hypertrophy .

**Key words :** X-ray Nasopharynx, Adenoid hypertrophy, Nasal endoscopy

### INTRODUCTION:

Adenoids, also known as nasopharyngeal tonsil, are an aggregation of submucosal lymphoid tissue. It is situated at the junction of the roof and posterior wall of the nasopharynx. It tends to show physiological enlargement upto 6 years of age thereafter regressing during puberty and completely disappearing by 20 years<sup>1,2</sup>. Adenoids obstruct the nasal airway to varying degrees resulting in nasal obstruction, nasal discharge, postnasal discharge and hyponasal speech (rhinolalia clausa). The subjective manifestations are dominated by chronic nasal obstruction which leads to mouth breathing during a period of active growth, resulting in development of the "adenoid facies"<sup>3,4</sup>. Also, the hypertrophied adenoid tissue can lead to the mechanical and/or inflammatory obstruction of the nasopharyngeal ostium of the auditory tube leading to Eustachian tube dysfunction, which is the starting point for almost all the acute or chronic otologic inflammatory processes and their consequences<sup>5</sup>. Diagnosing an obstructed posterior airway is not always a simple task because its location prevents direct observation. Different recommendations for the diagnosis of adenoid hypertrophy include lateral soft tissue radiograph of the nasopharynx, videofluoroscopy, transoral digital palpation, transoral mirror examination, nasal resistance and airflow test, nasoendoscopy and three-dimensional imaging. Each possesses positive and negative qualities. However, there is no consensus on the gold standard procedure for diagnosing posterior airway obstruction<sup>6</sup>. The lateral soft tissue radiograph of nasopharynx is perhaps the most commonly used of the above tests. It is a simple, economical, readily available and reproducible way to diagnose upper airway obstruction<sup>7</sup>. However it gets limited by two dimensional representation of a three dimensional space<sup>8</sup>. Nasal endoscopy is supplementary to the standard otorhinolaryngological examination that is indispensable to the evaluation of upper airway conditions in children. Our prospective study compares and evaluates the grading of adenoid hypertrophy by radiographic and nasal endoscopy methods.

### MATERIAL AND METHODS:

The study was conducted at Sri Guru Ram Das Institute of Medical Sciences and Research, Amritsar in the department of ENT and included 40 paediatric cases. The children in age group of 3-14 years with symptoms of nasal obstruction, nasal discharge, headache, post nasal discharge, voice change, earache, decrease hearing, defective speech, sleep apnoea, snoring and hyponasal speech were included in the

study. The patients less than 3 years and more than 14 years, those with past history of cleft palate repair and submucous cleft palate, with bleeding or coagulation defects, craniofacial abnormalities and patients having Down syndrome were not included. The selected patients were examined for the presence / absence of adenoid facies (an elongated dull expressionless face, prominent mouthcrowded upper teeth, hitched up upper lip, high arched palate and pinched in nose). A complete nasal examination; anterior and posterior rhinoscopy; aural examination, oral cavity and oropharynx examination, eustachian tube function tests (Valsalva technique, if possible) and general examination for lymphadenopathy and other relevant examination to exclude any other medical problem were done. The patients underwent a complete CBC, pure tone audiometry (if patient is cooperative) and Impedance Tympanometry. All patients in the study underwent a standard lateral soft tissue neck radiography in the Radiology Department. The radiographs were obtained with the children in the supine position and their neck slightly extended using a Siemens MULTIX machine. The x-ray field was collimated to the nasopharynx, with a focus film distance of 40 inches, using average exposure factors of 60 kV and 3.2 milli Ampere-seconds (mAs). The films were then assessed by the one single pediatric radiologist. AN ratio was calculated using Fujioka method and adenoid grading was done using method by Kurein et al on X-ray<sup>8,9,10</sup>. Grade 1; PA > 6.0 mm, Grade 2; PA 3.0 -6.0 mm, Grade 3; PA < 3.0 mm

Fig. 1: Grade 3 adenoid hypertrophy on Nasal endoscopy

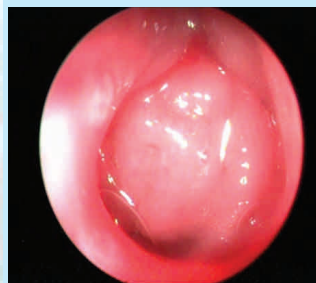
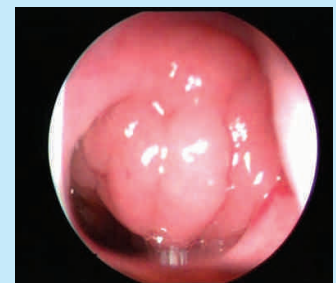

Fig. 2: Grade 4 adenoid hypertrophy on Nasal endoscopy



where PA is the air passage. A per-operative diagnostic nasal endoscopy in all 40 patients was done using 2.7-mm Karl Storz 0 degree rigid endoscope before adenoidectomy under general anaesthesia to obtain a full choanal image by the single surgeon to avoid subjective variability. The amount of obstruction was categorized through dividing the amount of obstruction to the full choanal surface that was expressed in 4 grades (Grade 0 : 0–25%, Grade 1 : 25–50%, Grade 2 : 50–75%, Grade 3 : 75–100%)<sup>9</sup>.

Nasal endoscopy was recorded using a DVD recorder. Afterward, only images of the adenoid were captured with a camera (Storz telecam). Pictures used for the calculation of the occupied parts were the pictures of the adenoid in which a full view of choana could be seen.

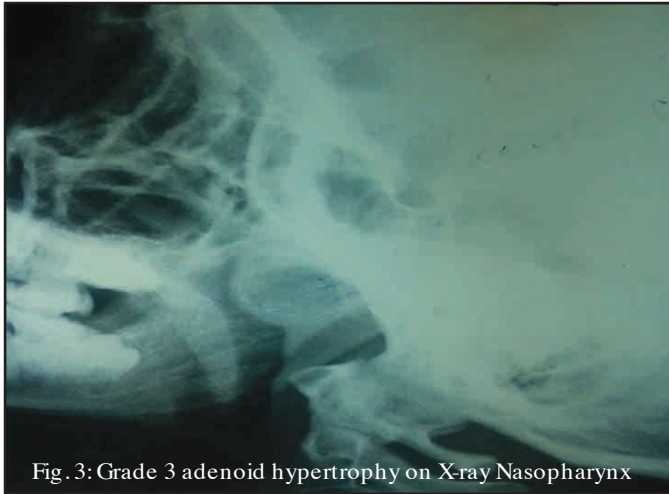

Fig. 3: Grade 3 adenoid hypertrophy on X-ray Nasopharynx

**RESULTS:**

The mean age of presentation was 7.5 years with 70% of cases as females and 30% as males Nasal obstruction (mouth breathing) was the most common complaint in our study, having 100% incidence, found in all 40 cases followed by nasal discharge found in 75% (30 of the 40), post-nasal discharge in 70% (28 of the 40) and snoring in 50%. Delayed defective speech and sleep apnoea showed an incidence of 2.5% each, seen in 1 of the 40 cases. Adenoid facies was the most consistent and constant feature on general examination in our study accounting for 75% incidence (30 of the 40 cases). On oral cavity examination, 92.5 % (37 of the 40) cases presented with open mouth and had high arched palate. Assessment of Adenoidal Nasopharyngeal (AN) ratio according to Fujioka Met al<sup>8</sup> on radiological evaluation of nasopharynx showed that 100 % (40 of the 40) cases had AN ratio within 0.73 - 0.99. The mean AN ratio was 0.79. Grading of adenoid hypertrophy on X-ray according to Kurein et al showed Grade III as the commonest with 17 out of 40 children followed by grade II (15 out of 40) and I (8 out of 40). (Table 1). Grading of adenoid hypertrophy according to Clemens and McMurray<sup>11</sup> on nasal endoscopy showed grade III adenoid hypertrophy as the most common grade followed by grade II and IV accounting for 62.5% (25 of the 40), 20% (8 of the 40) and 17.5% (7 of the 40) respectively (Table 2). Out of 15 cases which were grade II on X-ray only 5 were grade II on while 8 were upgraded to grade III and 2 to grade IV. Out of 8 cases which were grade I on X-ray no case was defined as grade I on endoscopy. The comparison is shown in Table 3

**DISCUSSION:**

Adenoidal hypertrophy and its measurement by clinical examination, imaging techniques, and endoscopic evaluation has been reported<sup>9</sup> However, the best method of adenoid hypertrophy diagnosis is a debatable topic. Many studies have been performed to propose the ideal method<sup>12,13</sup>. The imaging techniques of the nasopharynx to visualise enlarged adenoids still in use today are X-rays<sup>14</sup>. lateral radiograph gives a measure of the absolute size of the adenoids and also an assessment of its relation to the size of airway<sup>15</sup>. X-rays in the diagnosis of enlarged adenoid had been less popular by

**Tab. 1: Adenoid size based on lateral plain radiograph of post nasal space**

Adenoid size	Patients with adenoid hypertrophy (n=40)	
	No.	%
Grade 1	8	20
Grade 2	15	37.5
Grade 3	17	42.5

**Tab. 2: Adenoid grading according to endoscopy**

Adenoid grade	Patients with adenoid hypertrophy (n=40)	
	No.	%
IV	7	17.5
III	25	62.5
II	8	20
I	nil	nil

**Tab. 3: The relationship between adenoid sizes assessed by lateral X-ray and endoscope**

Adenoid size based on lateral x-ray	Adenoid grade based on nasoendoscope				Total
	I	II	III	IV	
Grade 1	—	3	4	1	8
Grade 2	—	5	8	2	15
Grade 3	—	—	13	4	17
Total	nil	8	25	7	40

*P=0.0001\* (Highly significant using Pearson chi-squared test at 0.05 level of significance)*

the turn of last century with the advent of nasal endoscopy, which is now considered to be the gold standard. Lateral skull radiograph is a noninvasive procedure which is well tolerated by children. Though nasal endoscopy is a easy method per-operatively but for pre-operative diagnosis the latter test however, has the disadvantage of being an invasive procedure<sup>9</sup>. Because of its two dimensional nature X-ray and the effects of positional changes and respiration movement of the patient, all these are examples of factors that may influence the findings and evaluation of the adenoid size by plain X-ray, leading to underdiagnosed adenoids in our study in some cases as compared to nasal endoscopy. The current findings were in agreement with Lourenco et al, who found that the mouth breather children who showed small adenoid by X-ray mostly had moderate size adenoid when examined by endoscopy, those with moderate size adenoid by the X-ray were mostly considered large by endoscope and lastly those with large adenoid seen by X-ray were also reported large by endoscope<sup>16</sup>. Some studies cite, the importance of endoscope in the assessment of adenoid enlargement in lateral direction rather than anterior direction which will be missed by routine X-ray of the postnasal space laterally<sup>17</sup>. Despite all the advantages of nasal endoscopy still X-rays are easy and more compliant to a child for diagnosis of adenoid hypertrophy. More so, though it has minor variations in grading than nasal endoscopy still it is at par with the latter as far as decision making for adenoidectomy is concerned.

**CONCLUSION:**

Nasal endoscopy is an emerging gold standard for diagnosis of adenoid hypertrophy but owing to the non invasive nature of X-ray it still serves as a reliable diagnostic tool. A preoperative X-ray combined with a per-operative nasal endoscopy are complementary to each other and serve in the best interest of the patient.

## REFERENCES:

1. Susan S, Harold E, Jermiah CH, David J, Andrew W. Pharynx. In: Livingstone C editors. Gray's anatomy: The Anatomical basis of Clinical Practice. 39th edition. Philadelphia: Elsevier. 2005; 619-31.
2. Vogler RC, Li FJ, Pilgram TK. Age specific size of the normal adenoid pad on magnetic resonance imaging. *Clinical Otolaryngology and Allied Sciences*. 2000; 25:392-5.
3. Zainea V. Conventional curettage adenoidectomy versus endoscopic assisted adenoidectomy. *Maedica*. 2011; 6(4):328-9.
4. O'Ryan FS, Gallagher DM, labanc JP, Epker BN. The relation between nasorespiratory function and dentofacial morphology: a review. *Am J Orthod*. 1982;82(5):403-10.
5. Sarafoleanu C, Enache R, Sarafoleanu D. Eustachian Tube Dysfunction of Adenoid Origin. *Therapeutics, Pharmacology and Clinical Toxicology*. 2010; 14(1):36-40.
6. Grewal N, Godhane AV. Lateral cephalometry: A simple and economical clinical guide for assessment of nasopharyngeal free airway space in mouth breathers. *Contemp Clin Dent*. 2010;1(2):669.
7. Mlynarek A, Tewfik MA, Hagr A, Manoukian JJ, Schloss MD, Tewfik T et al. Lateral neck radiography versus direct video rhinoscopy in assessing adenoid size. *J Otolaryngol*. 2004;33(6):360-5
8. Fujioka M, Young LW, Girdang BR. Radiographic evaluation of adenoidal size in children: Adenoidal-nasopharyngeal ratio. *American Journal of Radiology*. 1979; 133:401-4.
9. Kurien M, Lepcha A, Mathew J et al. X-Rays in the evaluation of adenoid hypertrophy: It's role in the endoscopic era. *Indian Journal of Otolaryngology and Head & Neck Surgery* 2005;57(1):45-47
10. Feres M, Sousa H, Francisco S et al. Reliability of radiographic parameters in adenoid evaluation. *Braz. J. otorhinolaryngol*. 2012;78(4):80-90
11. Clemens J, mcmurray JS, Willging JP. Electrocautery versus curette adenoidectomy: comparison of postoperative results. *Int J Pediatr Otorhinolaryngol*. 1998; 43(2):115-22.
12. Aparecida C, Roithm KR. Sensitivity and specificity of nasal flexible fiberoptic endoscopy in the diagnosis of adenoid hypertrophy in children. *Int J Pediatr Otorhinolaryngol* 2008; 72:63-7.
13. Wormald PJ, Prescott CA. Adenoids: comparison of radiological assessment methods with clinical and endoscopic findings. *J Laryngol Otol* 1992; 106:342-4.
14. Bershon JE, Sweeney JP, Jafek BW. The Tonsil and adenoids, Diagnostic Imaging of Waldeyer's ring: In *Otolaryngologic Clinics of North America*, AD Kornblut (Editor) WB Saunders: Philadelphia; 1987. p.229-34.
15. Hibbert J, Whitehouse GM. The assessment of adenoid size by radiological means. *Clin Otolaryngol* 1978; 3:43-7.
16. Lourenco EA, Lopez K de C., Pontes AJ., Oliveira M.H., Umemura A., Vargas A.L. Comparison between radiological and nasopharyngolaryngoscopic assessment of adenoid tissue volume in mouth breathing Children. *Rev Bras de Otorrinolaringologia*. 2005; 71(1) : 23-7.
17. Wright E.D., Pearl A.J., Manoukian J.J. hypertrophic adenoids as contributory factor in otitis media. *Int J Ped Otolaryngol*. 1998; 45: 207-14.