

Dutta H

Department of Speech & Hearing
Ganesh Man Singh Memorial Academy
of ENT-Head Neck Studies
Institute of Medicine(IOM)
Maharajgunj, Kathmandu, Nepal

Correspondence to:

Dr. Heempali Dutta
Ganesh Man Singh Memorial Academy
of ENT-Head & Neck Studies
Institute of Medicine(IOM)
Maharajgunj, Kathmandu, Nepal
E-mail:heempalidutta@hotmail.com

A RARE CASE OF MIKULICZ'S DISEASE**Abstract:**

Mikulicz's Disease is a form of Mikulicz's syndrome characterized by benign painless enlargement of bilateral lacrimal, parotid and submandibular glands which is because of dense infiltration of mononuclear cells. The disease is less severe form of Sjögren's syndrome and shows good response with steroid treatment.

Key words: Mikulicz's disease, Mikulicz's syndrome, Sjögren's syndrome

INTRODUCTION:

Mikulicz's disease (MD) is a rare idiopathic disorder characterized by benign painless enlargement of bilateral lacrimal, parotid and submandibular glands¹. It is mainly caused by dense infiltration of lymphocytes in salivary and lacrimal gland which may be secondary to enhanced immunologic response associated with several abnormal serum antibodies such as anti-Ro and anti-La⁴. The condition is thought to be a variant of a larger symptom complex, Sjögren's syndrome (SS), because of similar pathologic characteristics^{2,3}. 38 years old lady presented with the history of progressive swelling of bilateral submandibular, parotid and lacrimal areas for five years. It started with bilateral submandibular gland which progressed to bilateral parotid then to lacrimal gland which was painless and persistent. She had pulmonary tuberculosis for which she was treated with antitubercular drugs for eight months and declared cured. There was no history of dryness of mouth or eye, joint pain, skin rashes, no evening rise of temperature, weight loss, and cough. Lacrimal gland function was assessed by the Schirmer test which ruled out dry eye. Fine needle aspiration of right submandibular gland shows mature lymphocytes in various stages of development along with few degenerative cells. Ultrasonography of submandibular gland shows enlarged both submandibular glands with coarse echotexture with few cystic areas. Others investigations like ESR, urine routine, blood sugar, renal function test, thyroid function test were within normal limit. Similarly, antinuclear antibody, RA factor, serological tests for syphilis, hepatitis, HIV was negative. She underwent excision of right submandibular gland under general anaesthesia. Histopathological examination of excised gland shows marked lymphocystic infiltration with formation of lymphoid follicles having prominent germinal centre. There was marked atrophy of Acinic cells with mild to moderate ductal proliferation which is suggestive of benign lymphoepithelial lesion. She was treated with oral prednisolone 1mg/kg in tapering dose over a period of 6 weeks. There was moderate decrease in size of lacrimal and salivary gland swelling after 6 weeks of steroid treatment. She was advised to follow up after one month but she was lost to follow up.

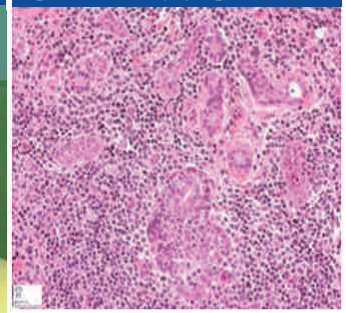
DISCUSSION:

Mikulicz's syndrome was described by Johann von Mikulicz-Radecki in 1888⁵. Mikulicz's Disease is a form of Mikulicz's syndrome which has the following features:

Fig.1: Swelling of bilateral submandibular, parotid and lacrimal areas

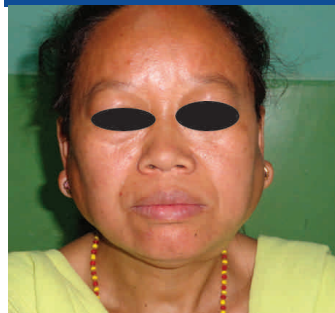

Fig.2: Atrophy of the acinar parenchyma and diffuse replacement by lymphoid tissue



Visual confirmation of symmetrical and persistent swelling in more than two lacrimal and major salivary glands
Prominent mononuclear cell infiltration of lacrimal and salivary glands, and
Exclusion of other diseases that present with glandular swelling such as sarcoidosis and lymphoproliferative disease⁶.

Histologic examination in MD reveals atrophy of the acinar parenchyma and diffuse replacement by lymphoid tissue. Similar clinical and histopathological picture was also observed in our case. In 1953, Morgan and Castleman described the relation between MD and Sjögren's syndrome, with the identical morphologic appearance of the salivary and lacrimal glands of the two diseases^{2,3}. They also noted similar symptoms and associated conditions (including keratoconjunctivitis sicca, xerostomia, and rheumatoid arthritis) and concluded that the condition characterized by chronic enlargement of the salivary and lacrimal glands, which had previously been called MD, may be a less highly developed variant of Sjögren's syndrome. MD mainly affects middle-aged or elderly females. The average age is 58.6 years (range 25–73 years) with a sex ratio of approximately 3: 1 in favor of females¹. Whereas the sex ratio for SS is usually approximately 20:1 (female:male)⁷. The enlargement of the lacrimal and salivary glands in MD patients is found to be elastic, painless, and

persistent (occurring for more than 3 months). Half of the MD patients do not exhibit keratoconjunctivitis sicca. Secretion of salivary glands in MD is normal or slightly decreased, and this improves with steroid treatment. The lacrimal and salivary swelling in SS present repeatedly and disappears without treatment. The sicca symptoms are also severe in SS. There were a few reports on the efficacy of a low dose of prednisolone on saliva production in patients with primary SS. Systemic corticosteroids are used for treating only severe extraglandular diseases, including diffuse interstitial pneumonia, glomerulonephritis, vasculitis, and peripheral neuropathy^{8,10}. The impact of steroids on the natural course of SS is not well established. The clinical figures of MD are thus quite different from those of typical SS. Mikulicz's disease is mainly treated by the administration of steroids (prednisolone at 30–40 mg/day) without organ failure. This leads to rapid improvement in glandular swelling as well as in lacrimal and salivary secretion¹. The long-term prognosis of MD is unknown. Among SS patients, the incidence of non-Hodgkin's lymphoma is 43.8-fold higher than the prevailing incidence in the general population¹¹. Sugai classified the severity of SS into three stages: stage I, having only sicca symptoms; stage II, having systemic organ involvement; and stage III, is complicated by lymphoma. Glandular and extraglandular SS may thus be considered as an early stage of lymphoma¹². There have also been reports on malignant transformation in MD¹³. Recently, Ihrler and Harrison speculated that the first MD case reported by Mikulicz in 1892 was MALT lymphoma based on Mikulicz's sketch of the specimen¹⁴. As there is no data available on long-term prognosis of MD, continuous analysis of complicating lymphoma in MD is necessary.

REFERENCES:

1. Motohisa Y, Hiroki T, et al. A new conceptualization for Mikulicz's disease as an IgG4-related plasmacytic disease. *Mod Rheumatol*. 2006 December; 16(6): 335–340.
2. Morgan W, Castleman B. A clinicopathologic study of "Mikulicz's Disease.". *Am J Pathol*. 1953;29:471–503.
3. Morgan W. The probable systemic nature of Mikulicz's disease and its relation to Sjögren's syndrome. *N Engl J Med*. 1954;251:5–10.
4. Talal N, Bunim J. The development of malignant lymphoma in the course of Sjögren's syndrome. *Am J Med*. 1964;36:529–540.
5. Mikulicz J. Über eine eigenartige symmetrische Erkrankung der Thränen- und Mundspeicheldrüsen. *Stuttgart: Beitr. z. Chir. Festschr. f. Theodor Billroth*; 1892. pp. 610–30. .
6. Yamamoto M, Takahashi H, Sugai S, Imai K. Clinical and pathological characteristics of Mikulicz's disease (IgG4-related plasmacytic exocrinopathy). *Autoimmunity Rev*. 2005;4:195–200. doi: 10.1016/j.autrev.2004.10.005.
7. Whitacre CC. Sex differences in autoimmune disease. *Nat Immunol*. 2001;2:777–80. doi: 10.1038/ni0901-777. .
8. Tzioufas AG, Moutsopoulos HM. Sjögren's syndrome. In: Klippel JH, Dieppe PA, editors. *Rheumatology*. 2nd ed. London: Mosby; 1998. pp. 7.32.1–7.32.12.
9. Moutsopoulos HM, et al. Sjögren syndrome. In: Braunwald E, Fauci AS, Kasper DL, Hauser SL, Longo DL, Jameson JL, et al., editors. *Harrison's principles of internal medicine*. 15th ed. New York: McGraw-Hill; 2001. pp. 1947–9.
10. Naguwa S, Gershwin ME. Sjögren syndrome. In: Goldman L, Ausiello D, editors. *Cecil textbook of internal medicine*. 22nd ed. Philadelphia: Saunders; 2004. pp. 1677–80.
11. Kassan SS, Thomas TL, Moutsopoulos HM, Hoover R, Kimberly RP, Budman DR, et al. Increased risk of lymphoma in sicca syndrome. *Ann Intern Med*. 1978;89:888–92.
12. Sugai S. Sjögren syndrome (in Japanese) *Nippon Naika Gakkai Zasshi*. 1999;88:1896–903.
13. Lopez-Enriquez E, Ceballos L, Cintron J, Gonzalez E. Malignant transformation in Mikulicz's disease. *Bol Asoc Med P R*. 1980;72:1–6.
14. Ihrler S, Harrison JD. Mikulicz's disease and Mikulicz's syndrome: analysis of the original case report of 1892 in the light of current knowledge identifies a MALT lymphoma. *Oral Surg Oral Med Pathol Oral Radiol Endod*. 2005;100:334–9.